

## Effect of chromium-methionine and zinc-methionine supplementation on histological changes of Awassi lamb testicles

Aslam Saud Alwan Hamad<sup>1\*</sup>, Shaymaa Ali Hassan<sup>2</sup>

<sup>1</sup>Department of Animal Production, College of Agriculture, Tikrit University, Iraq; Aslam.alwan@tu.edu.iq (A.S.A.H.).

<sup>2</sup>Department of Biology, College of Education for Women, Tikrit University, Iraq.

**Abstract:** This study was conducted in the sheep field of the Animal Production Department at the College of Agriculture / Tikrit University for the period 25 October 2021 to 1 February 2022 (70 days) with the aim of measuring the effect of adding both Chromium- Methionine (Cr-M) and Zinc Methionine (Zn-M) on histological changes in the testicles of Awassi lambs. 24 lambs aged 4-5 months were distributed equally into four groups (group / 6 lambs), the initial weight was  $25.35 \pm 2.25$  kg, the first group (T1) was not given only the basic feed (control), the second group added 1 gm Cr-M / 100 kg of live weight, the third group was given 0.33 gm of Zn-M / 100 live weight and the fourth group was given 1 gm Cr-M + 0.33 gm Zn-M / 100 live weight. Tissue samples were taken from the testicles of lambs up on removal from the body, and the changes and histological components were studied using fixation and staining techniques to study the changes in the seminiferous tubules and interstitial cells including the thickness of the basement membrane. The results showed that treatment with T2 and T3 led to a significant improvement in the histological structures of the testicle, as well as an increase in the diameter of the seminiferous tubules and an increase in the thickness of the basement membrane. It was noted that there was an increase in the activity of sperm formation compared to the control group. Moreover, the T4 group was the most responsive to treatment, as the results showed a significant improvement in all histological parameters, as well as an increase in the density of sperm cells, and a decrease in amyloid deposition and necrosis. From this, we conclude that the addition of Cr-M and Zn-M, especially when added together, improves the health of the testicles and supports the production of sperm cells.

**Keywords:** Chromium-methionine, Histology, Lambs, Zinc-methionine.

### 1. Introduction

The past years have witnessed interest in using trace minerals as nutritional supplements, the aim of which was to improve animal health in general and reproductive performance in particular. Among these materials are chromium methionine and zinc methionine, which are organic mineral elements, especially in the nutrition of ruminant animals, including sheep that live in arid environments and are characterized by scarcity of feed, as rare minerals play an important role in enhancing the efficiency of the body's metabolic action in addition to being an antioxidant, especially in the field of fertility by supporting cell function and hormonal regulation [1]. Understanding the effect of these substances on testicular tissue is very important [2] and of utmost importance, as changes in tissue structure of testicle have a direct effect on reproductive efficiency in general and sperm formation in particular [3, 4]. Trace minerals, especially chromium and zinc, are essential for synthesis of hormones, enzymatic reactions [5] and immune functions in livestock [6]. Zinc is very important for sperm production, testosterone synthesis [7] testicular development, as well as enhancing glucose metabolism and insulin sensitivity [8] which enhances energy for the reproductive tissues [9] such as chromium methionine and zinc methionine it is an organic forms of minerals [10] can provide significantly superior absorption compared to their inorganic counterparts, resulting in improved antioxidant capacity and

metabolic activity [11, 12]. The role of zinc in male fertility has been widely discussed, as it effectively contributes to sperm formation, DNA synthesis, and cells divisions [13]. Conversely, testicular function is impaired when this element is deficient, which is reflected in the quality of sperm and the appearance of deformities in the structure of the testicle [14]. It has been proven that the use of chromium methionine supplements has the ability to increase the size of the testicle, increase the diameter of the seminiferous tubules, and also increase the concentration of sperm in both sheep and goats [15]. In addition to the above, chromium plays an important role in the metabolism process (energy) and the body's defense (antioxidants), in terms of its presence during periods of stress, in addition to during times of sexual reproduction [16]. The addition of chromium methionine as a supplement reduces oxidative stress, improves glucose uptake and provides support for cell energy production, all of which improve sperm viability and testicular function [17, 18]. Several studies have shown that dietary supplements containing chromium and zinc enhance the synergistic benefits of the two elements, and increase support for metabolic processes and testicular tissue structure [19]. Effects include increased diameter of the seminiferous tubules, thickness of the basement membrane, and increased spermatogenesis [20, 21]. Antioxidants work to reduce oxidative damage by binding to these supplements and maintaining tissue integrity and function [22]. Based on the reproductive and economic importance of lambs, following the strategy of using trace mineral supplements is of great importance which provides a complete view of the changes that occur in the testicular tissues and their fertility. Perhaps the most important thing that previous scientific sources rely on in evaluating the effectiveness of supplements, whether chromium methionine or zinc methionine, in warming the testicular tissues, in addition to this focus on the morphological changes that occur in the seminiferous tubules and the density of sperm cells and the appearance of signs of necrosis or amyloid deposition, by searching for the interaction of trace elements and testicular tissues, this research may contribute to the development of sustainable nutritional programs that support the reproductive and productive performance of Awassi lambs.

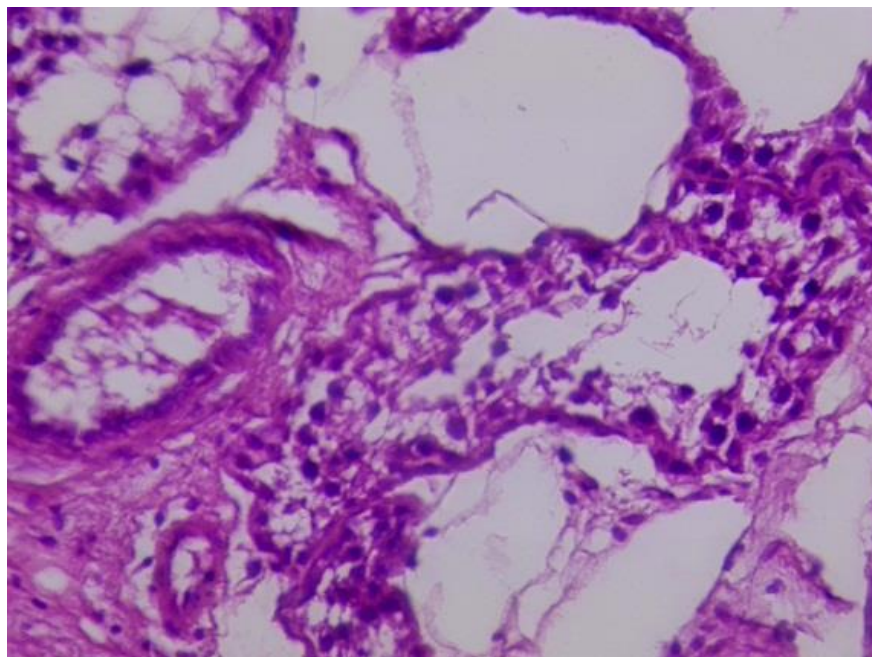
## 2. Materials and Methods

The experiment was conducted in the animal production laboratory of the Animal Production Department at the College of Agriculture - Tikrit University for the period from 10/25/2021 to 1/2/2022. In order to study the evaluation of the effect of treatment with chromium-methionine (Cr-M) and zinc-methionine (Zn-M) on the tissue structures of the testicles of Awassi lambs, 24 lambs aged 4-5 months and weighing  $25.36 \pm 2.25$  kg were randomly distributed into four treatments: T1: Control group fed the basic diet without additives, T2: fed the basic diet with the addition of 1 gm Cr-M /100 kg live weight, T3: fed the basic diet with the addition of 0.33 gm Zn-M /100 kg live weight, T4: fed the basic diet with the addition of the mixture of Cr-M 1 gm and Zn-M 0.33/100 kg live weight. The lambs were subjected to a 14-day lambing acclimatization period. The basic diet consisted of concentrate and roughage. The nutritional requirements of the lambs were calculated based on the recommendations of the National Research Council (1985). The hay was provided at a rate of 3% of the lamb's live body weight and divided into two meals, morning and evening. Water was available ad libitum. At the end of the 70 days testes were taken from healthy lambs from Salahuddin/Tikrit slaughterhouse. After testis removal, they were washed with normal saline (0.9% NaCl), and after cleaning the testes, they were placed in a special box, and immediately fixed in neutral buffered formalin NBF10% at room temperature. Routine histological technique was performed, dehydrating each sample in seven sequential stages in different concentrations of ethanol, twice in xylene, one hour each time for filtration, finally, impregnating the samples by two runs in melted paraffin wax (58-60 °C) for two hours each step. using a digital tissue processor. Then, using a semi-digital embedding center containing special molds to make wax blocks. Finally, the slides are sectioned into 5-micrometer-thick slices using a semi-digital rotary microtome, and each slice is then stained with: To reveal the general histological structures, Harris hematoxylin and eosin stain are used, to describe the general histological structures, Weigerts iron hematoxylin stain, periodic acid stain (PAS) Seminiferous tubules in the testicular lobule are used. Measurements included intratubular germ cell density, Sertoli cell and interstitial cell volume, tissue necrosis was analyzed by estimating damage or oxidative stress, and amyloid deposition in the

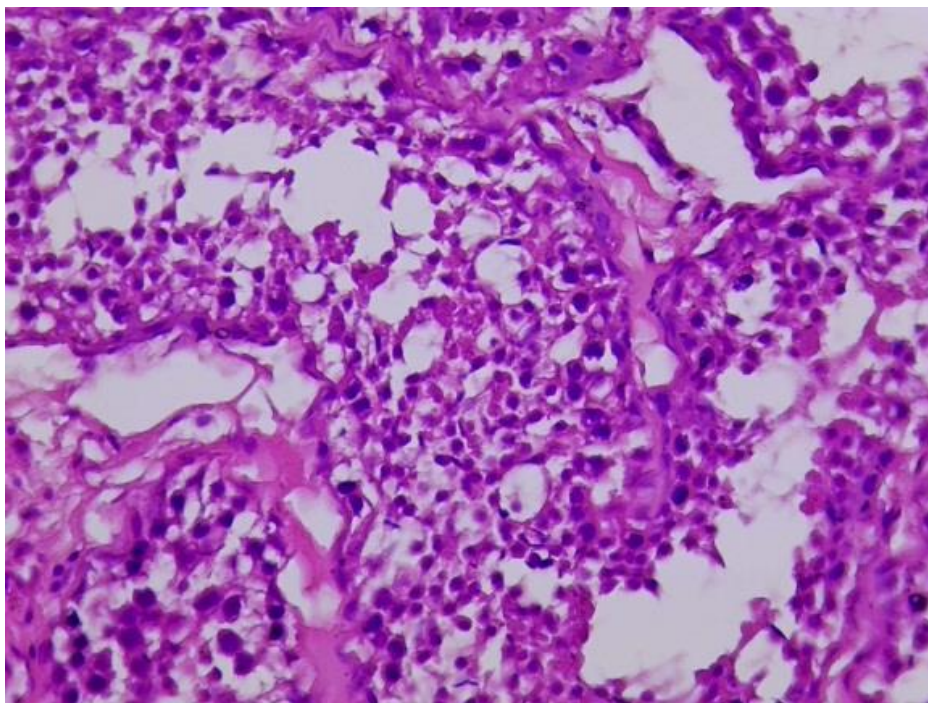
tubules. Measurements also included interstitial cell density. These measurements provide a comprehensive examination of the health of testicular tissues under the influence of nutritional supplements such as chromium and zinc.

### 3. Results and Discussion

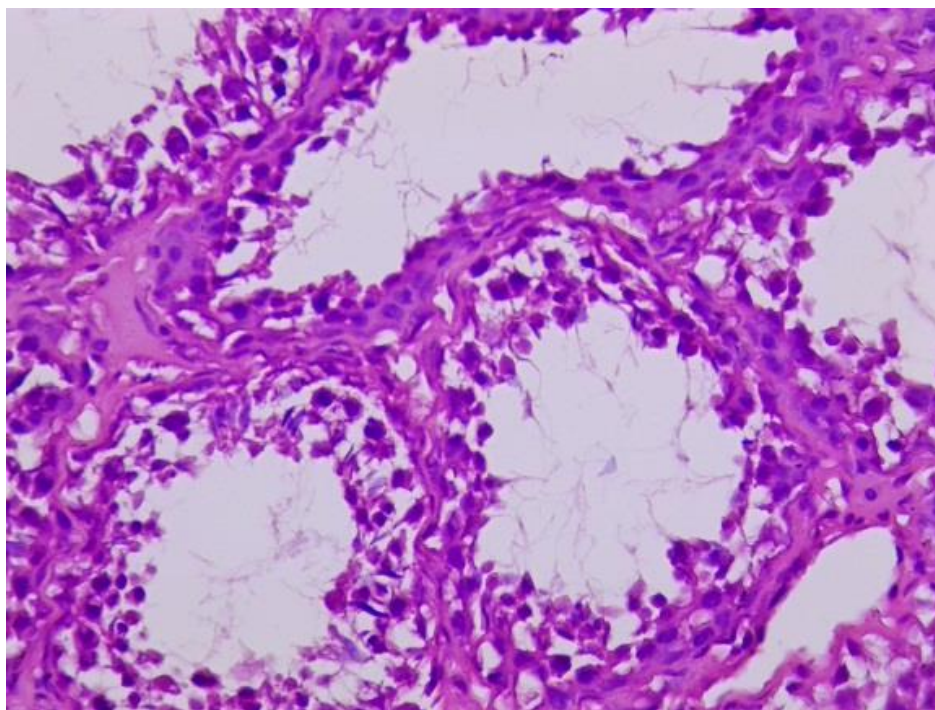
The results of the study showed that the histological changes of the testicles of lambs treated with chromium-met and zinc-met were clearly different and many histological variables were studied. In figures 1,2, and 3 for the control T1 as can be seen, this group showed a clear deterioration in the histological changes compared to the other treated. Signs of tissue deterioration such as necrosis between the seminiferous tubules, deposition of abnormal fluids in interstitial spaces observed. These changes indicate a deterioration in testicular function due to negative effects of oxidation and lack of mineral additive. the results showed the histological changes in the testicles of Awassi lambs, signs of histological deterioration such as decreased activity of sperm production, and accumulation of abnormal fluids in interstitial spaces of the seminiferous tubules, as it appears amyloid fluids. It is noted in the control group T1, which showed a clear deterioration in most of the histological changes compared to all the treated groups, as signs of tissue deterioration were observed, like necrosis between the seminiferous tubules and deposition of abnormal fluids in the interstitial spaces. These changes as a results negative effect of oxidation and deficiency indicate a deterioration in the testicular function due to deficiency in mineral supplements. In addition, the testicles of the lambs showed signs of histological deterioration, such as a decrease in the activity of sperm production, and the accumulation of abnormal fluids inside the interstitial spaces of the seminiferous tubules, such as starchy fluids.



**Figure 1.**  
T1: Section of testicular tissue with irregularly shaped seminiferous tubules and obvious interstitial necrosis.

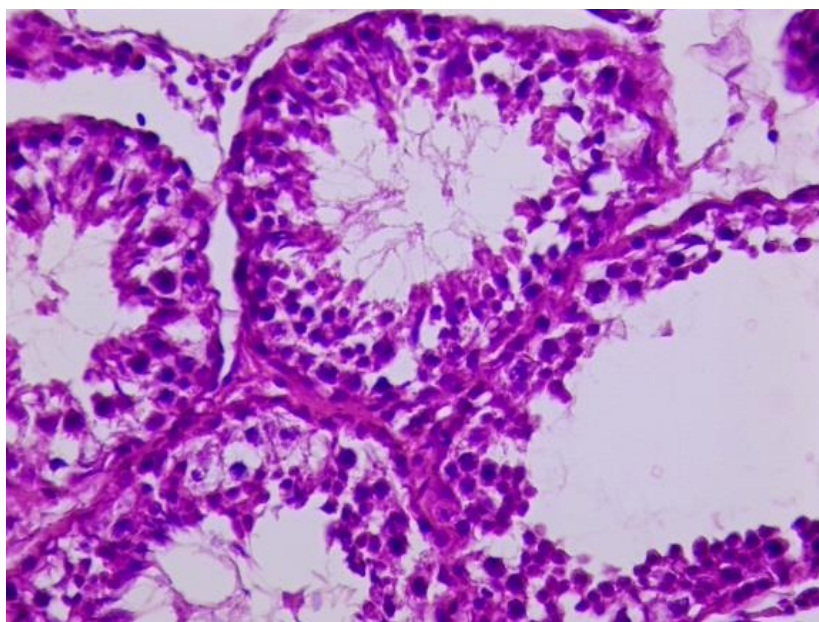


**Figure 2.**  
T1: showing deposition of starchy fluids inside the seminiferous tubule causing weakness in the overall structure of the tissue.



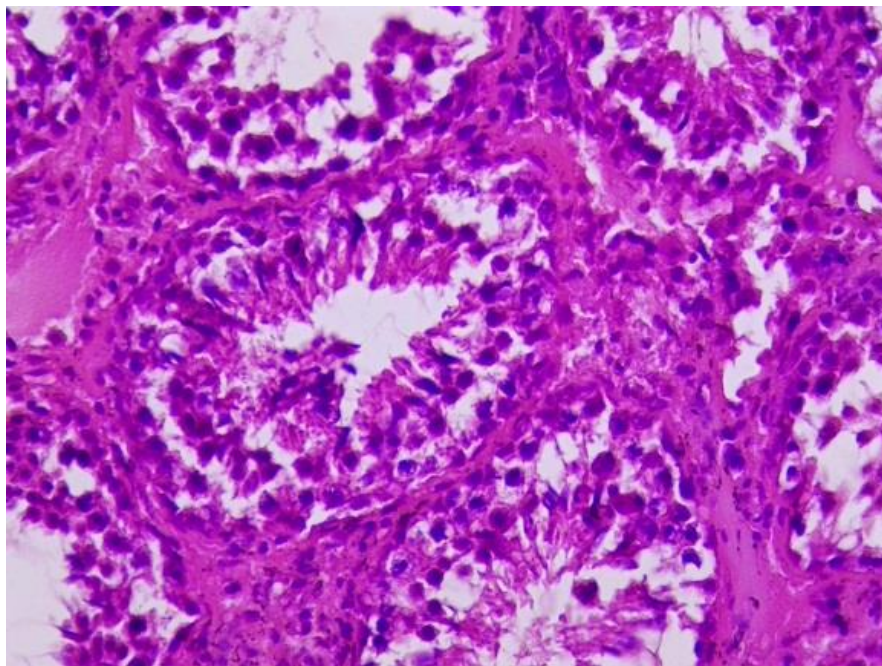
**Figure 3.**  
T1: showing deterioration of Sertoli cells, Leydig cells in addition to decreased sperm activity and impaired tissue integrity.

It is noted that there is a deterioration in the tissues in the control group, which may be attributed to the deficiency of supplements such as chromium and zinc, which in turn leads to a state of oxidative stress within the testicular tissues [23]. The absence of supplements leads to the accumulation of free radicals and toxic substances resulting from metabolic processes, which causes damage to the sperm-producing cells [24]. Kumar and Singh [25] pointed to deficiency of chromium and zinc leads to a disruption of cell functions, especially Sertoli cells which play a major role in nourishing supporting and supporting the sperm. Zinc deficiency can lead to decreased production of sex hormones [26] such as testosterone TS contributing to poor testicular function [27]. Treatment tow T2 which was given Cr-Met as shown in the figures 4, 5 and 6 showed moderate improvements in histological structure of testicles, with increased diameter of the seminiferous tubules and thickness of the basement membrane reflecting greater activity in sperm cells [28]. A decrease in amyloid deposition was also observed, suggesting a role of chromium in reducing oxidative damage within the reproductive tissues [29]. Reason behind the structural improvement Methonine is an essential element in improving absorption of minerals better in the animal's body as it acts as a cofactor in enhancing the availability of vital minerals such as chromium and zinc [30]. Chromium is known for its ability to reduce oxidative stress that negatively affects testicular cells [31]. Zinc is also essential for sperm formation and improving their function in the testes and the minerals contribute to maintaining the structure of the seminiferous tubules and Sertoli cells thus positively affecting sperm production [13]. The elements that have ability to reduce oxidative stress that negatively affects testicular cells Mehranfrooz, et al. [31]. Mehranfrooz, et al. [31] and Mehranfrooz, et al. [31] showed that chromium-methionine supplementation significantly improved structure of testicular tissue, improving diameter of seminiferous tubules and increasing number of sperm-producing cells. study by Kumar and Singh [25] showed that zinc-methionine supplementation contributed to reducing oxidative damage and increasing density of sperm-producing cells in testes in lamb. Another study by Kumar and Singh [25] showed that zinc and methionine supplementation reduced oxidative damage and increased density of sperm-producing cells in ram testes.

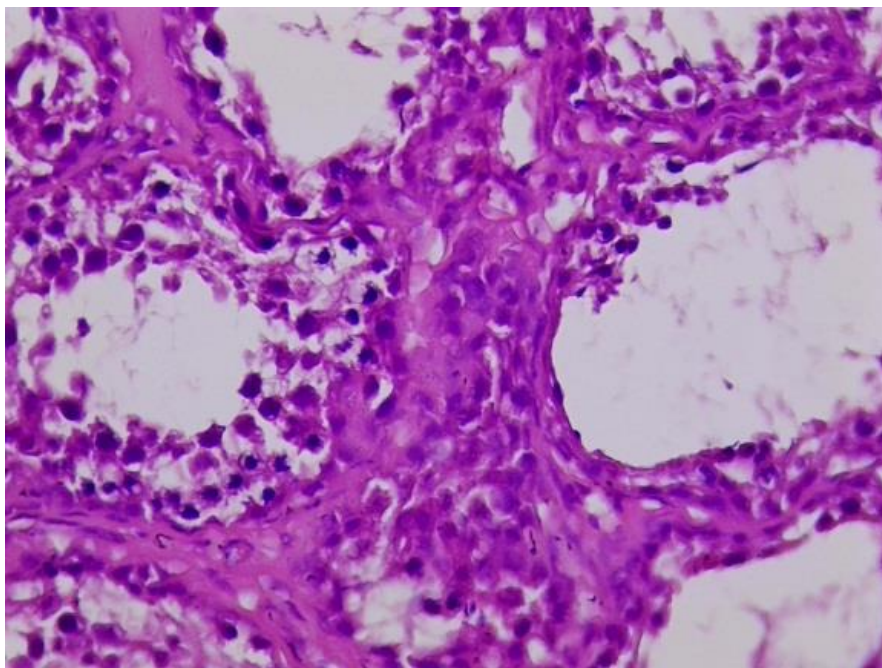


**Figure 4.**

Treatment 2 (Cr-Met) T2: seminiferous tubules have slightly larger diameters and thicker epithelial layers compared with control group, indicating some improvement in tissue structure.



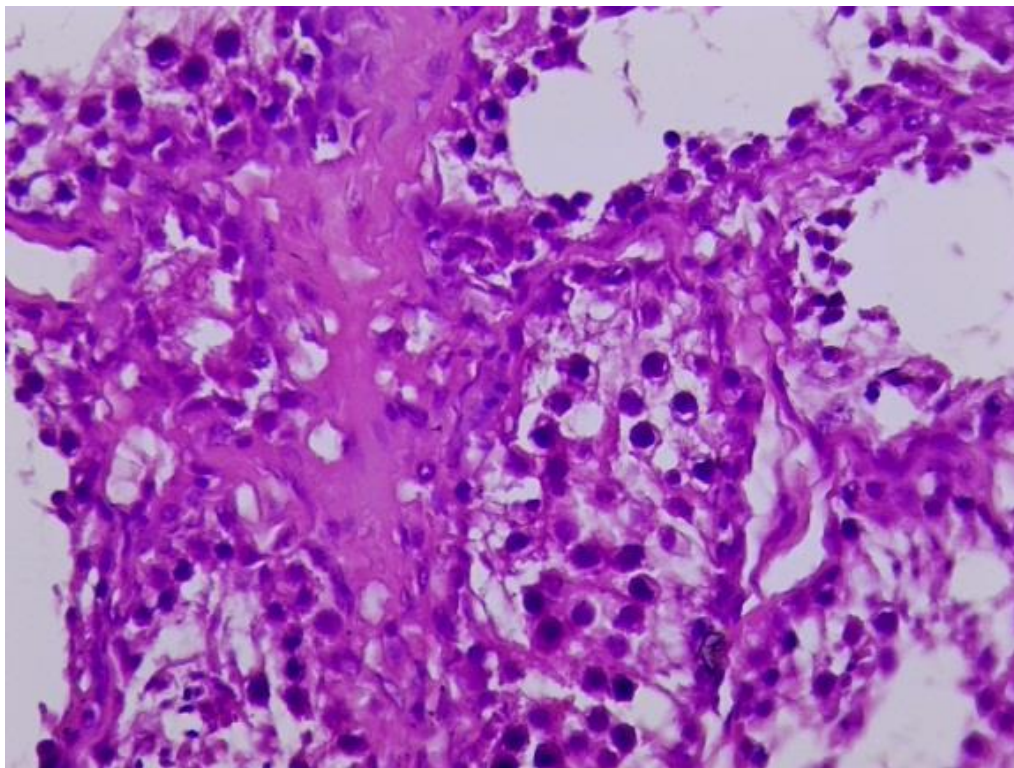
**Figure 5.**  
Treatment 2 (Cr-Met) T2: It shows lower starch deposition and less interfacial necrosis, reflecting the protective effects against oxidative stress of chromium.



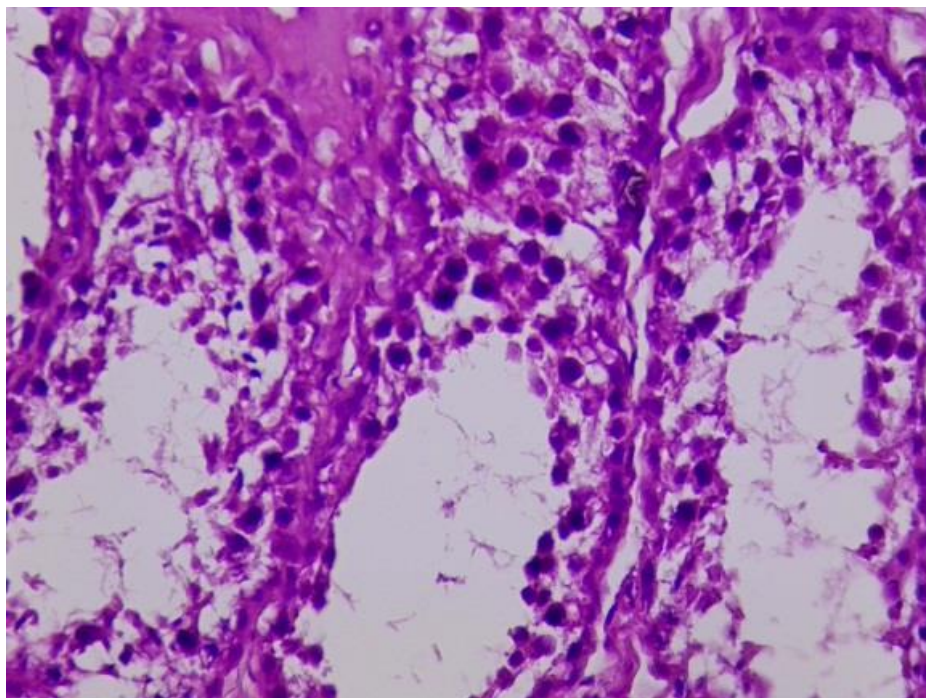
**Figure 6.**  
Treatment 2 (Cr-Met) T2: Sertoli and Leydig cells are healthier, with increased spermatogenic activity compared to the control group.

In the third group T3 (Zn-Met), Figures (7, 8 and 9) showed a significant improvement in histological changes, as well as an increase in the activity of sperm-producing cells, as well as a decrease in dead areas in the tissues between the seminiferous tubules. This improvement is likely attributed to

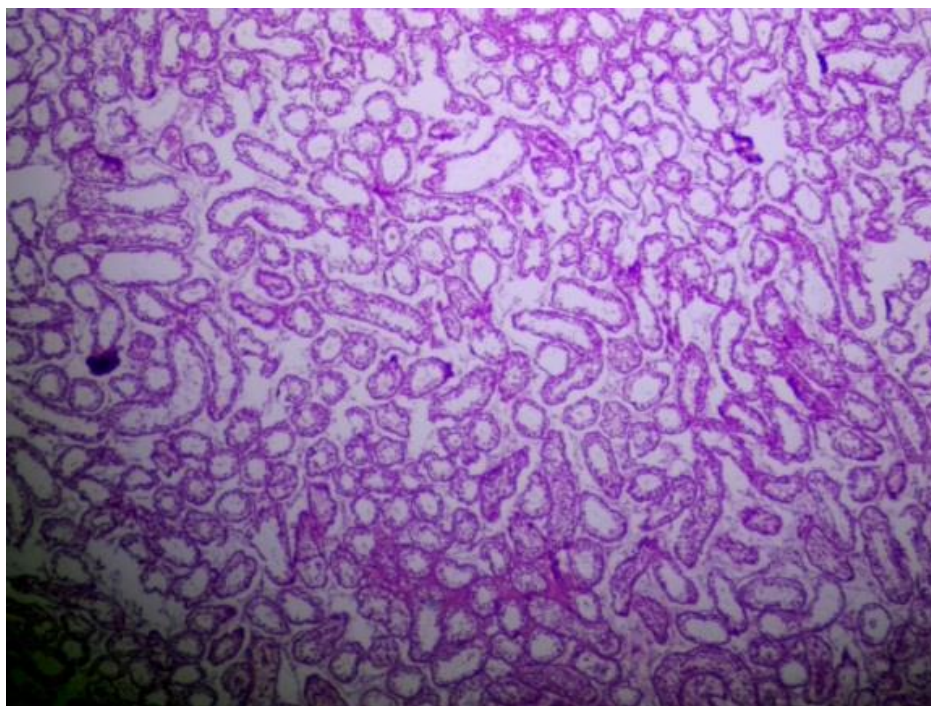
the ability of zinc to promote cell health and reduce oxidative damage, which may help maintain the integrity of the testicular tissue. The role of zinc in cell division, protein synthesis and maintenance of the integrity of the blood-testicular barrier may have facilitated these improvements [32]. The increased presence of healthy cells in the testes (Sertoli and Leydig) further supports the hypothesis that zinc supplementation contributes to a better environment for spermatogenesis. While the third treatment showed a significant improvement. Zinc is also essential for sperm formation and sperm function in the testicles. Minerals contribute to maintaining the structure of the seminiferous tubules and Sertoli cells, thus positively affecting sperm production [13].



**Figure 7.** Treatment 3 (Zn-Met) T3: The seminiferous tubules appear to have a more regular shape and improved diameter, indicating the positive effects of zinc supplementation on testicular structure.



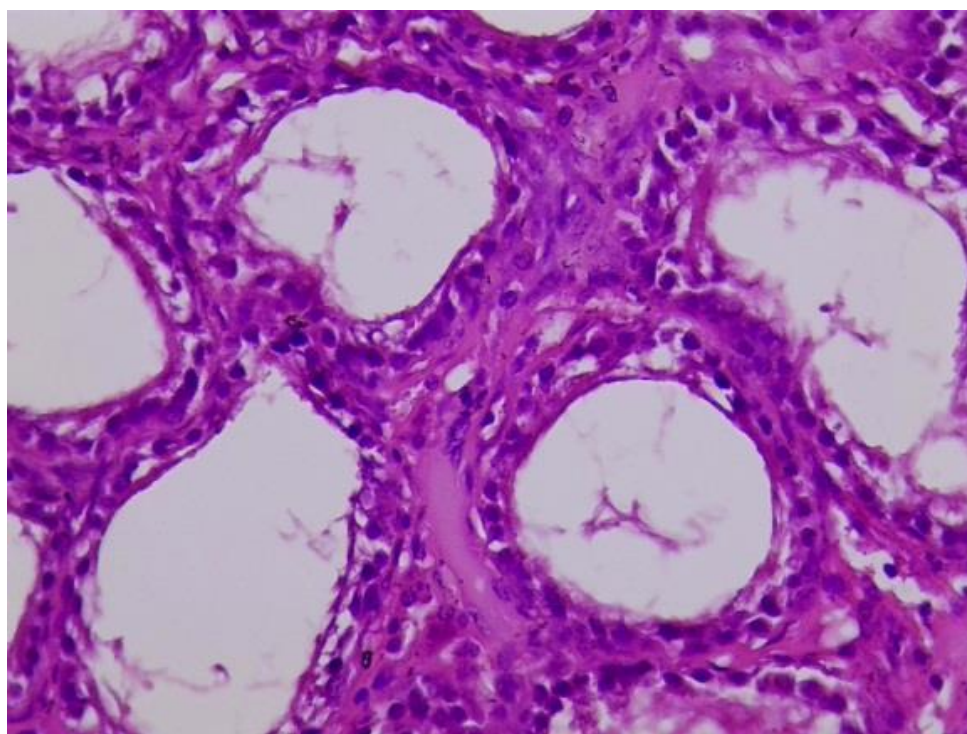
**Figure 8.**  
Treatment 3 (Zn-Met) T3: It shows reduced dead areas and few damaged cells in the interstitial tissue, indicating the beneficial role of zinc in maintaining cell integrity.



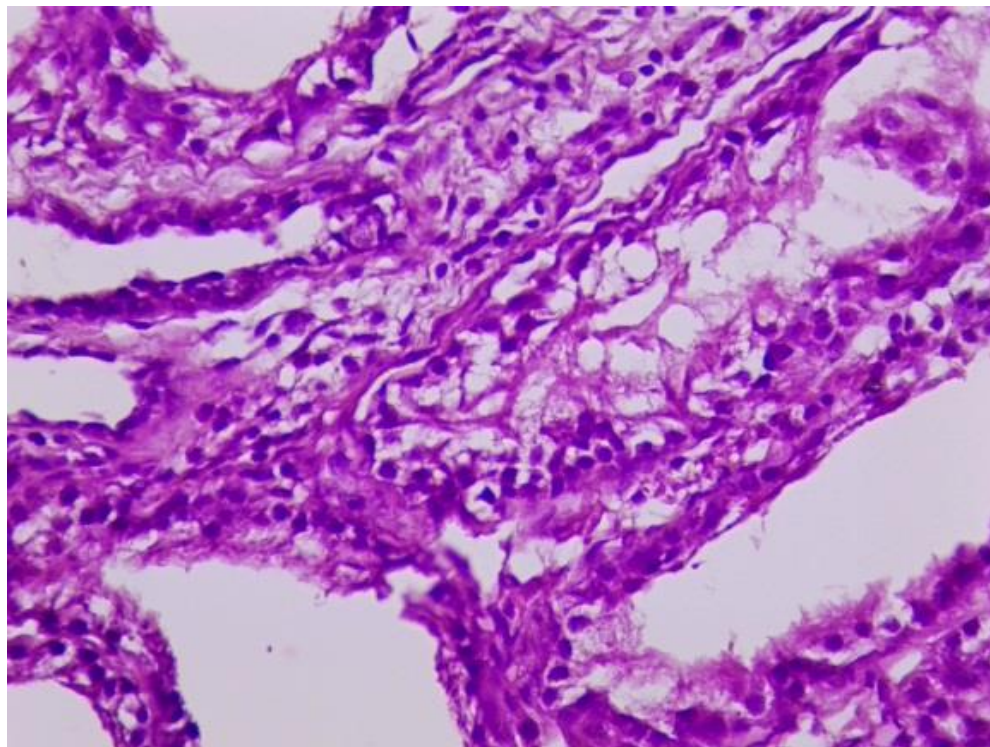
**Figure 9.**  
Treatment 3 (Zn-Met) T3: Shows better developed Sertoli and Leydig cells, generally increased spermatogenesis and improved tissue health.



The most effective was the fourth group T4, which consisted of a mixture of chromium methionine and zinc methionine, as is clear in Figures 10, 11 and 12, as it showed a significant improvement in all the parameters under study, as a significant increase in the diameter of the seminiferous tubules and the thickness of the seminiferous epithelium was observed compared to the rest of the groups, as well as an increase in the density of sperm-producing cells and, in contrast, a significant decrease in indicators of necrosis or tissue degeneration. In addition, the accumulation of starchy fluids decreased, which had a positive effect on the health of the testicle and protected it from oxidative damage. The most important thing that these results indicate is that the combination of chromium methionine and zinc methionine enhances the ability of the testicles to produce sperm and improves the tissue environment in general. Limwachirakhom, et al. [33] reported that the combination of Chromium (CrM) and zinc (Zn) makes the synergistic effect, of the two elements work to enhance the action of antioxidants. Chromium (CrM) improves glucose metabolism [34] and provides energy for tissue repair and regeneration [35] while zinc acts on cell membranes [36] strengthening and stabilizing them, reducing the effects of oxidative stress (OXD), which improves the health of reproductive cells [13, 37]. In addition, Cr and Zn together improve the reproductive activity [38] of sertoli cells and expand tissues, within the seminiferous tubules, which enhances sperm production and improves their quality [39]. A study by Fallah, et al. [13] showed that chromium improves sperm ability to swimming, while zinc enhances the health of producing sperm cells. As Egwurugwu, et al. [40] pointed out, supplementation with elements such as Zn and Cr enhances the ability to combat oxidative stress (OXD), which reduces tissue and cell damage in the testicles and improves their overall function.

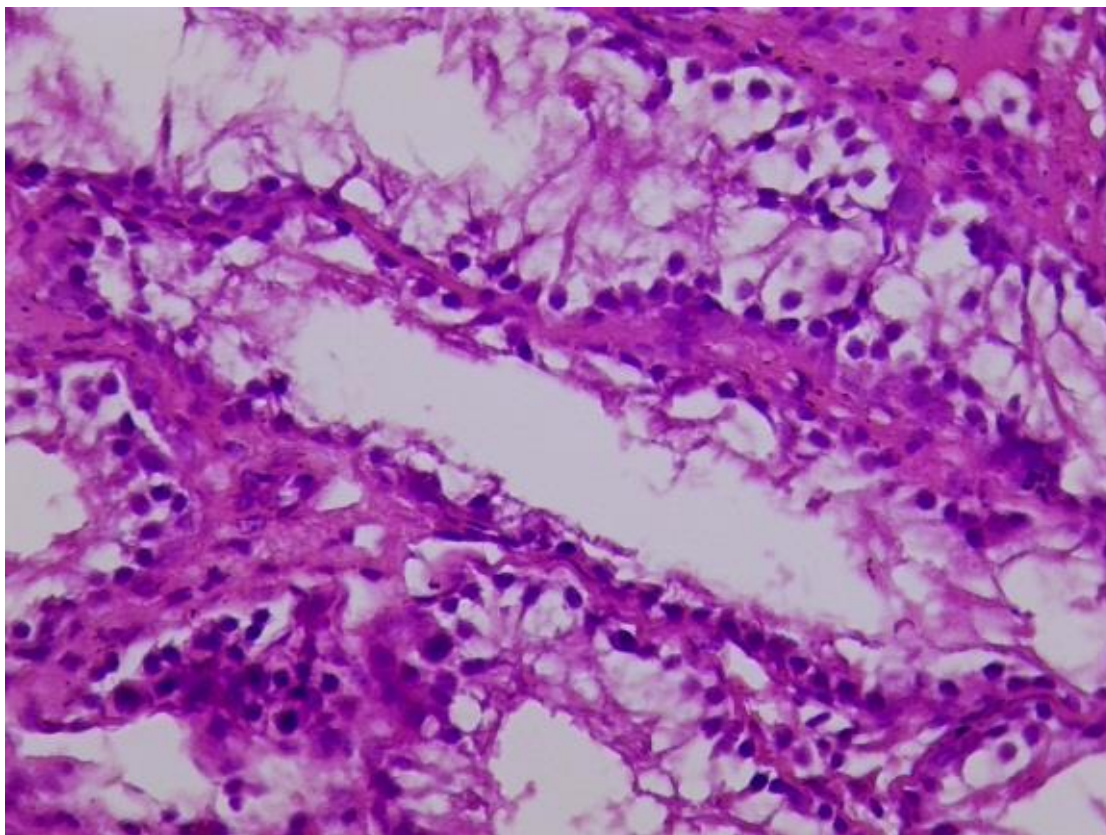


**Figure 10.** Treatment 4 (Cr-Met + Zn-Met) T4: The seminiferous tubules appear larger in diameter and the epithelium is thicker compared to all treatments, reflecting a significant improvement in the tissue.



**Figure 11.**

Treatment 4 (Cr-Met + Zn-Met) T4: shows a significant decrease in dead zones and less starchy fluid deposition, which clearly demonstrates the synergistic effects of chromium and zinc in preventing oxidative damage.



**Figure 12.**

Treatment 4 (Cr-Met + Zn-Met) T4: shows a significant increase in sperm-producing cells, an increase in Sertoli and Leydig cells, confirming the combined beneficial effects on spermatogenesis and testicular health.

Histological analysis of testicular tissues of the four treatments T1, T2, T3 and T4 revealed significant differences in the function and structure of the seminiferous tubules, as well as the integrity of the supporting cells involved in spermatogenesis. Control group was not treated with any supplements, showed very clear refers to tissue deterioration, including in interstitial cells necrosis and deposition of amyloid fluid within the seminiferous tubules, suggests that a deficiency of Chromium (CrM) and zinc (Zn) supplements led to oxidative stress, which damaged the structural components of the testicles and impaired cellular function [41]. This study Study compatible with previous studies Kumar and Singh [25] and Srivastava, et al. [27] that showed the deficiency of essential minerals, such as Zn and CrM, can lead to cell damage and thus decreased spermatogenesis activity.

As for the second treatment (T2) (CrM and methionine) showed moderate improvement in testicular tissue as the Ghoul, et al. [42] pointed out, as well as increased seminiferous tubule diameter and significantly decreased amyloid deposition [43] compared to the control group. It is likely that the role of chromium, which has antioxidant properties and enhances glucose metabolism, may have contributed to these improvements by reducing oxidative stress and promoting cell repair [44]. These results are in line with other studies, where chromium supplementation has shown improvement in testicular morphology and sperm production in males [38]. However, these improvements were less pronounced compared to those observed in the T4.

The fourth treatment T4 fed with a combination of Cr-Methionine and Zn-Methionine outperformed all other treatments, showing greater improvement in testicular tissue. Combination of CrM resulted increase in seminiferous tubule diameter, enhanced cell integrity, especially in Sertoli and Leydig cells, and increased thickness of the seminiferous epithelium [45]. This synergistic effect is likely to reduce oxidative damage more effectively than any other mineral alone, leading to healthier

testicular tissue and improved spermatogenesis [26]. These results were agreement with Khalid and Alwan [46] which indicated that the combined effect of CrM and ZnM promotes cell repair, enhances antioxidant capacity, and improves overall reproductive function. The combination of CrM and ZnM has been shown to be the most effective strategy on reproductive efficiency in Awassi lambs and improving testicular health.

#### 4. Conclusion

In this study concluded chromium-methionine CrM and ZnM supplements its results were significant effect on T4 achieved the best results in terms of increasing sperm cell density and improving testicular tissue, and reducing damage caused by oxidative stress. More studies recommended to understand the exact mechanisms and nature of the effect of these supplements at the physiological level.

#### Copyright:

© 2025 by the authors. This article is an open access article distributed under the terms and conditions of the Creative Commons Attribution (CC BY) license (<https://creativecommons.org/licenses/by/4.0/>).

#### References

- [1] V. K. Mayasula *et al.*, "Trace minerals for improved performance: a review of Zn and Cu supplementation effects on male reproduction in goats," *Tropical Animal Health and Production*, vol. 53, pp. 1-8, 2021. <https://doi.org/10.1007/s11250-021-02943-5>
- [2] H. Zheng, Y. Hu, M. Shao, S. Chen, and S. Qi, "Chromium picolinate protects against testicular damage in STZ-induced diabetic rats via anti-inflammation, anti-oxidation, inhibiting apoptosis, and regulating the TGF- $\beta$ 1/Smad pathway," *Molecules*, vol. 28, no. 22, p. 7669, 2023. <https://doi.org/10.3390/molecules28227669>
- [3] M. Hedger, "Immunology of the testis and male reproductive tract," *Comprehensive Toxicology*, pp. 189-220, 2010. <https://doi.org/10.1016/b978-0-08-046884-6.01112-x>
- [4] N. Asadi, M. Bahmani, A. Kheradmand, and M. Rafeian-Kopaei, "The impact of oxidative stress on testicular function and the role of antioxidants in improving it: a review," *Journal of Clinical and Diagnostic Research*, vol. 11, no. 5, p. IE01, 2017.
- [5] M. Nasiadek, J. Stragierowicz, M. Klimczak, and A. Kilanowicz, "The role of zinc in selected female reproductive system disorders," *Nutrients*, vol. 12, no. 8, p. 2464, 2020. <https://doi.org/10.1007/s10534-023-00527-4>
- [6] R. A. Palomares, "Trace minerals supplementation with great impact on beef cattle immunity and health," *Animals*, vol. 12, no. 20, p. 2839, 2022. <https://doi.org/10.3390/ani12202839>
- [7] L. Te, J. Liu, J. Ma, and S. Wang, "Correlation between serum zinc and testosterone: A systematic review," *Journal of Trace Elements in Medicine and Biology*, vol. 76, p. 127124, 2023. <https://doi.org/10.1016/j.jtemb.2022.127124>
- [8] Y. Tamura, "The role of zinc homeostasis in the prevention of diabetes mellitus and cardiovascular diseases," *Journal of Atherosclerosis and Thrombosis*, vol. 28, no. 11, pp. 1109-1122, 2021. <https://doi.org/10.5551/jat.rv17057>
- [9] L. R. McDowell, *Minerals in animal and human nutrition*. San Diego: Academic Press, 2003.
- [10] E. Yenice, C. Mızrak, M. Gültekin, Z. Atik, and M. Tunca, "Effects of organic and inorganic forms of manganese, zinc, copper, and chromium on bioavailability of these minerals and calcium in late-phase laying hens," *Biological Trace Element Research*, vol. 167, pp. 300-307, 2015. <https://doi.org/10.1007/s12011-015-0313-8>
- [11] J. W. Spears, "Trace mineral bioavailability in ruminants," *The Journal of Nutrition*, vol. 133, no. 5, pp. 1506S-1509S, 2003. <https://doi.org/10.1093/jn/133.5.1506s>
- [12] Y. Xiong *et al.*, "Dietary replacement of inorganic trace minerals with lower levels of organic trace minerals leads to enhanced antioxidant capacity, nutrient digestibility, and reduced fecal mineral excretion in growing-finishing pigs," *Frontiers in Veterinary Science*, vol. 10, p. 1142054, 2023. <https://doi.org/10.3389/fvets.2023.1142054>
- [13] A. Fallah, A. Mohammad-Hasani, and A. H. Colagar, "Zinc is an essential element for male fertility: A review of Zn roles in men's health, germination, sperm quality, and fertilization," *Journal of Reproduction & Infertility*, vol. 19, no. 2, p. 69, 2018.
- [14] M. I. Yattoo *et al.*, "Role of trace elements in animals: a review," *Veterinary World*, vol. 6, no. 12, p. 963, 2013.
- [15] B. Roy, R. Baghel, T. Mohanty, and G. Mondal, "Zinc and male reproduction in domestic animals: A review," *Indian Journal of Animal Nutrition*, vol. 30, no. 4, pp. 339-350, 2013.
- [16] National Research Council, *Nutrient requirements of small ruminants: Sheep, goats, cervids, and new world camelids*. National Academy Press, 2007.
- [17] I. M. Youssef, I. M. Abdo, H. F. Elsukkary, M. F. El-Kady, and M. Elsayed, "Effects of dietary supplementation of chromium methionine chelate on growth performance, oxidative stress, hematological indices, and carcass traits of broiler chickens," *Tropical Animal Health and Production*, vol. 54, no. 5, p. 267, 2022. <https://doi.org/10.1007/s11250-022-03260-1>

- [18] M. I. Yousef, F. M. El-Demerdash, K. I. Kamil, and F. A. Elswad, "Ameliorating effect of folic acid on chromium (VI)-induced changes in reproductive performance and seminal plasma biochemistry in male rabbits," *Reproductive Toxicology*, vol. 21, no. 3, pp. 322-328, 2006. <https://doi.org/10.1016/j.reprotox.2005.09.005>
- [19] A. S. Mohamed *et al.*, "Efficacy of dietary supplementation with zinc-chromium mixture, organic selenium, or their combinations on growth performance, carcass traits, and blood profiles of broilers under heat stress conditions," *Animals*, vol. 13, no. 15, p. 2539, 2023. <https://doi.org/10.3390/ani13152539>
- [20] P. M. Nair *et al.*, "Impact of zinc, copper, manganese and chromium supplementation on growth performance and blood metabolic profile of Sahiwal (Bos Indicus) male calves," *Biomaterials*, vol. 36, no. 6, pp. 1421-1439, 2023.
- [21] S. H. Suede, A. Malik, and A. Sapra, "Histology, Spermatogenesis. (2023). In: StatPearls. Treasure Island (FL): StatPearls Publishing; 2024 Jan-." 2020.
- [22] P. Celi and S. Chauhan, "Oxidative stress management in farm animals: Opportunities and challenges," presented at the 4th International Conference on Sustainable Animal Agriculture for Developing Countries (SAADC2013), 2013.
- [23] R. Aitken and S. Roman, "Antioxidant systems and oxidative stress in the testes," *Oxidative Medicine and Cellular Longevity*, vol. 1, no. 1, pp. 15-24, 2008. <https://doi.org/10.4161/oxim.1.1.6843>
- [24] G. Walke, S. S. Gaurkar, R. Prasad, T. Lohakare, and M. Wanjari, "The impact of oxidative stress on male reproductive function: Exploring the role of antioxidant supplementation," *Cureus*, vol. 15, no. 7, p. e42583, 2023. <https://doi.org/10.7759/cureus.42583>
- [25] N. Kumar and A. K. Singh, "Role of zinc in male infertility: review of literature," *Indian Journal of Obstetrics and Gynecology Research*, vol. 3, no. 2, pp. 167-171, 2016. <https://doi.org/10.5958/2394-2754.2016.00028.x>
- [26] A. E. Omu *et al.*, "Molecular basis for the effects of zinc deficiency on spermatogenesis: An experimental study in the Sprague-dawley rat model," *Indian Journal of Urology*, vol. 31, no. 1, pp. 57-64, 2015. <https://doi.org/10.4103/0970-1591.139570>
- [27] A. Srivastava, M. Thakur, S. Mahra, V. P. Singh, S. Sharma, and D. K. Tripathi, "Zinc nutrition to plant, animals, and humans: recent updates," in *Zinc in Plants*: Elsevier, 2025, pp. 323-338.
- [28] L. B. Smith and W. H. Walker, "The regulation of spermatogenesis by androgens," in *Seminars in Cell & Developmental Biology*, 2014, vol. 30: Elsevier, pp. 2-13.
- [29] A. K. Chandra, A. Chatterjee, R. Ghosh, and M. Sarkar, "Effect of curcumin on chromium-induced oxidative damage in male reproductive system," *Environmental Toxicology and Pharmacology*, vol. 24, no. 2, pp. 160-166, 2007. <https://doi.org/10.1016/j.etap.2007.04.009>
- [30] S. Vijayaram, E. Ringo, A. Zuorro, H. van Doan, and Y. Sun, "Beneficial roles of nutrients as immunostimulants in aquaculture: A review," *Aquaculture and Fisheries*, vol. 9 no. 5, pp. 707-720, 2023. <https://doi.org/10.1016/j.aaf.2023.02.001>
- [31] A. Mehranfrooz, A. Ahmadi, and M. Yavari, "Semen quality and biochemistry and blood antioxidant status in Mehraban rams supplemented with organic selenium alone or combined with organic chromium during the summer," 2022.
- [32] C. Y. Cheng, D. D. Mruk, and D. R. Sibley, "The blood-testis barrier and its implications for male contraception," *Pharmacological Reviews*, vol. 64, no. 1, pp. 16-64, 2012. <https://doi.org/10.1124/pr.110.002790>
- [33] R. Limwachirakhom, S. Triwatanon, S. Chumkam, and O. Jintasatoporn, "Effects of chromium-l-methionine in combination with a zinc amino acid complex or selenomethionine on growth performance. Intestinal Morphology, and Antioxidative Enzymes in Red Tilapia Oreochromis spp," *Animals*, vol. 12, no. 17, p. 2182, 2022. <https://doi.org/10.3390/ani12172182>
- [34] W. T. Cefalu, Z. Q. Wang, X. H. Zhang, L. C. Baldor, and J. C. Russell, "Oral chromium picolinate improves carbohydrate and lipid metabolism and enhances skeletal muscle Glut-4 translocation in obese, hyperinsulinemic (JCR-LA corpulent) rats," *The Journal of Nutrition*, vol. 132, no. 6, pp. 1107-1114, 2002. <https://doi.org/10.1093/jn/132.6.1107>
- [35] J. Bertinato and P. Griffin, "A low chromium diet increases body fat, energy intake and circulating triglycerides and insulin in male and female rats fed a moderately high-fat, high-sucrose diet from peripuberty to young adult age," *Plos one*, vol. 18, no. 1, p. e0281019, 2023.
- [36] B. L. O'Dell, "Role of zinc in plasma membrane function," *The Journal of Nutrition*, vol. 130, no. 5, pp. 1432S-1436S, 2000.
- [37] D. d. N. Marreiro, K. J. C. Cruz, J. B. S. Morais, J. B. Beserra, J. S. Severo, and A. R. S. De Oliveira, "Zinc and oxidative stress: Current mechanisms," *Antioxidants*, vol. 6, no. 2, p. 24, 2017. <https://doi.org/10.3390/antiox6020024>
- [38] S. C. Pereira, P. F. Oliveira, S. R. Oliveira, M. d. L. Pereira, and M. G. Alves, "Impact of environmental and lifestyle use of chromium on male fertility: focus on antioxidant activity and oxidative stress," *Antioxidants*, vol. 10, no. 9, p. 1365, 2021. <https://doi.org/10.3390/antiox10091365>
- [39] S. Marín de Jesús *et al.*, "Zinc and its impact on the function of the testicle and epididymis," *International Journal of Molecular Sciences*, vol. 25, no. 16, p. 8991, 2024. <https://doi.org/10.3390/ijms25168991>
- [40] J. Ekwurugwu, C. Ifedi, R. Uchefuna, E. Ezeokafor, and E. Alagwu, "Effects of zinc on male sex hormones and semen quality in rats," *Nigerian Journal of Physiological Sciences*, vol. 28, no. 1, pp. 17-22, 2013.
- [41] A. B. Harchegani, H. Dahan, E. Tahmasbpour, H. B. Kaboutaraki, and A. Shahriary, "Effects of zinc deficiency on impaired spermatogenesis and male infertility: the role of oxidative stress, inflammation and apoptosis," *Human fertility (Cambridge, England)*, vol. 23, no. 1, pp. 5-16, 2020. <https://doi.org/10.1080/14647273.2018.1494390>

- [42] A. Ghoul, B. Chaouad, Y. Benazzoug, and J.-M. Exbrayat, "Effects of methionine chronic administration on testicular tissue in rats: A histopathological and immunohistochemical study," *International Journal of Morphology*, vol. 42, no. 5, 2024.
- [43] E. Abd Elhafeez, "Effects of Cadmium and/or Chromium on reproductive organs and semen profiles of male albino rats," *Mansoura Veterinary Medical Journal*, vol. 20, no. 3, pp. 14-18, 2019.
- [44] M.-H. Lai, "Antioxidant effects and insulin resistance improvement of chromium combined with vitamin C and E supplementation for type 2 diabetes mellitus," *Journal of Clinical Biochemistry and Nutrition*, vol. 43, no. 3, pp. 191-198, 2008. <https://doi.org/10.3164/jcbn.2008064>
- [45] Y. Jin and Y. Zhou, "Effects of concentrate level and chromium-methionine supplementation on the performance, nutrient digestibility, rumen fermentation, blood metabolites, and meat quality of Tan lambs," *Animal Bioscience*, vol. 35, no. 5, p. 677, 2021. <https://doi.org/10.5713/ab.20.0802>
- [46] M. Khalid and A. Alwan, "Effect of adding Chromium-Methionine and Zinc-Methionine on production performance and some hormones in the blood of Awassi lambs," *Tikrit Journal for Agricultural Sciences*, vol. 23, no. 1, pp. 59-66, 2023. <https://doi.org/10.25130/tjas.23.1.8>